



Clinical Cases in

*Early Prosthetic Loading of STERI-OSS Implant
Clinical Outcomes and Osseointegration Assessment*

by Dr. Lee, Daehee, DDS, MSD, Ph.D

- Adjunct Professor, College of Dentistry, Seoul National University, Seoul, Korea
- Adjunct Professor, Sanggye Paik Hospital, Seoul, Korea
- Director, Cho Hoon Dental Clinic, Seoul, Korea
- Advisor, F & I Implant Research, Seoul, Korea

STERI-OSS IMPLANT

Abstract

This study evaluates the clinical performance of STERI-OSS Implant, focusing on survival rates, secondary stability assessed via ISQ values, and marginal bone resorption.

A total of 77 implants placed between March 2019 and May 2020 were examined with a follow-up period ranging from three months to over a year. Prosthetic loading was initiated approximately two months after the fixture placement.

The results demonstrated successful osseointegration with ISQ values predominantly ranging from 80 to 90, indicating excellent secondary stability. No cases of marginal bone resorption exceeding 1 mm were observed. While these findings suggest the reliability of STERI-OSS Implant, further longitudinal studies with larger patient cohorts are necessary to validate long-term outcomes.

Keywords

- STERI-OSS Implant
- Osseointegration
- ISQ Values
- Marginal Bone Resorption
- Prosthetic Loading
- Early Prosthetic Loading (Approximately Two Months Post-Placement)

1. Introduction

Dental implants have become a widely accepted solution for edentulism, providing long-term functional and aesthetic benefits. The success of an implant is influenced by multiple factors, including implant design, surgical technique, bone quality, and post-operative care.

This study aims to evaluate the clinical outcomes STERI-OSS Implant, particularly focusing on survival rates, ISQ values, and marginal bone resorption to assess their short-term reliability and efficiency.

2. Materials and Methods

2.1 Study Design and Period

- Study Period: February 2019 – May 2021
- Sample Size: 77 implants in 51 patients
- Follow-up Period: 3 months to over 1 year

2.2 Implant Types and Distribution

<i>Implant Type</i>	<i>Number of Implants Used for Case Study</i>
SD4508	24 pcs
SD5007	13 pcs
SD5008	9 pcs
SD4510	8 pcs
Others (SD4007, 4008, 4009, 4010, etc.)	23 pcs

2.3 Implant Placement Criteria

- Posterior single implants: Diameter ≥ 5.0 mm
- Premolar single implants: Diameter ≥ 4.5 mm
- Anterior implants: Predominantly 4.0 mm, with adjustments for narrow buccolingual ridge

2.4 Follow-up Examination Methods

- Panoramic and periapical radiographs used for post-operative assessment

3. Results

3.1 Implant Survival Rate

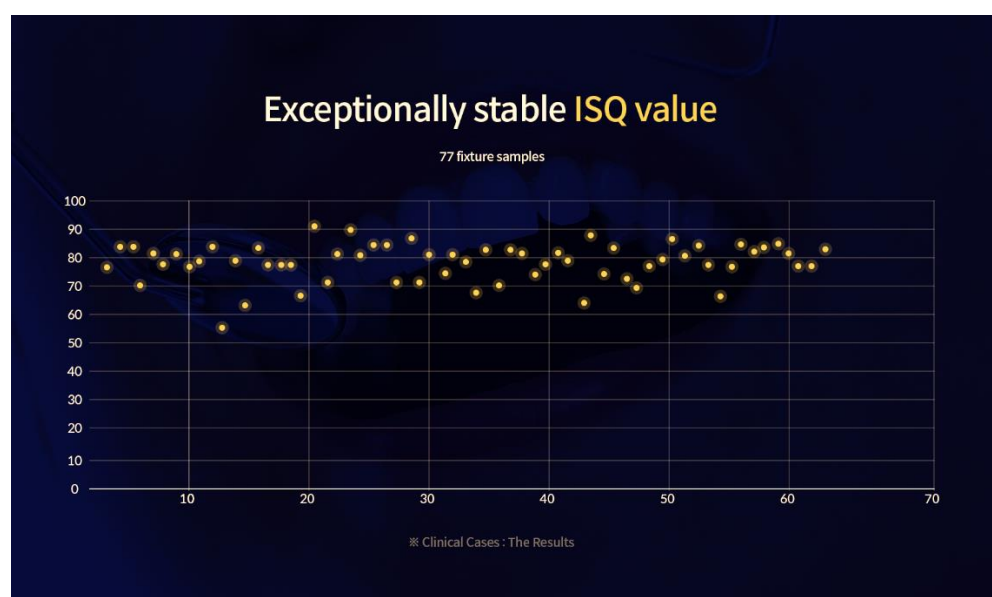
- All 77 implants functioned successfully without complications.

3.2 Implant Stability (ISQ Values)

- Study Period: February 2019 – May 2021
- ISQ recorded at two stages: impression taking (~2 months' post-op) and abutment placement (~2 weeks later).
- Majority showed ISQ values between 80-90, indicating excellent stability.
- Two implants exhibited ISQ values in the 60s.

3.3 Marginal Bone Resorption

<i>Follow-up Period</i>	<i>Cases of Marginal Bone Loss > 1mm</i>
<i>3-6 months</i>	0
<i>6-12 months</i>	0
<i>>1 year</i>	0



4. Discussion

The findings in this study demonstrate the promising performance of STERI-OSS Implant. High survival rates and ISQ values indicate excellent secondary stability, while the absence of significant marginal bone resorption suggests a favorable short-term prognosis.

However, limitations such as the relatively small sample size and short follow-up duration highlight the need for additional long-term research. Expanding the study with a larger patient cohort will provide a more comprehensive understanding of STERI-OSS Implant clinical performance.

5. Conclusion

Despite compromised bone quality necessitating bone grafting or the placement of short implants, this study demonstrated a high success rate, excellent ISQ values, and minimal marginal bone loss. These findings suggest that STERI-OSS Implant provide a predictable and effective solution for short-term implant therapy. However, future longitudinal studies with extended observation periods and larger sample sizes are recommended to further validate these results.

6. Clinical Photographic Description

The following clinical images illustrate the osseointegration process and short-term prognosis of the STERI-OSS Implant analyzed in this study.

Each image was taken at various time points, from immediate post-placement to post-prosthetic loading, to assess marginal bone stability and overall implant success.

The 77 fixture placement cases included in this study predominantly involved compromised bone quality, as demonstrated in the accompanying clinical and radiographic documentation. Consequently, many cases required bone grafting or the placement of short implants due to insufficient bone volume. Despite these challenging conditions, ISQ values consistently ranged between 80 and 90, indicating excellent secondary stability. Additionally, no cases of marginal bone resorption exceeding 1 mm were observed, demonstrating the outstanding clinical performance of the STERI-OSS Implant, even in less-than-ideal bone conditions.

These clinical and radiographic findings confirm that STERI-OSS Implant achieve excellent secondary stability, demonstrate high survival rates, and exhibit minimal marginal bone loss, even in cases involving poor bone quality or bone augmentation procedures.

[Case 1]

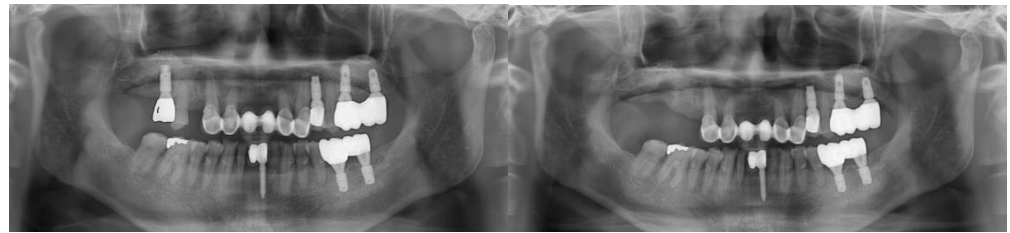
Implant-supported 4-unit bridge with bone graft in the posterior maxilla, with financial consideration

▫ **Treatment Plan:** Tooth #15 exhibited vertical mobility, and the screw loosening of implant #16 had persisted for a long time. However, the patient did not visit the clinic until after the loss of tooth #14, which resulted in the inability to chew on the right side. Due to financial constraints, the patient decided to proceed with the minimal necessary implant treatment.

▫ **Implant Placement:** March 2019

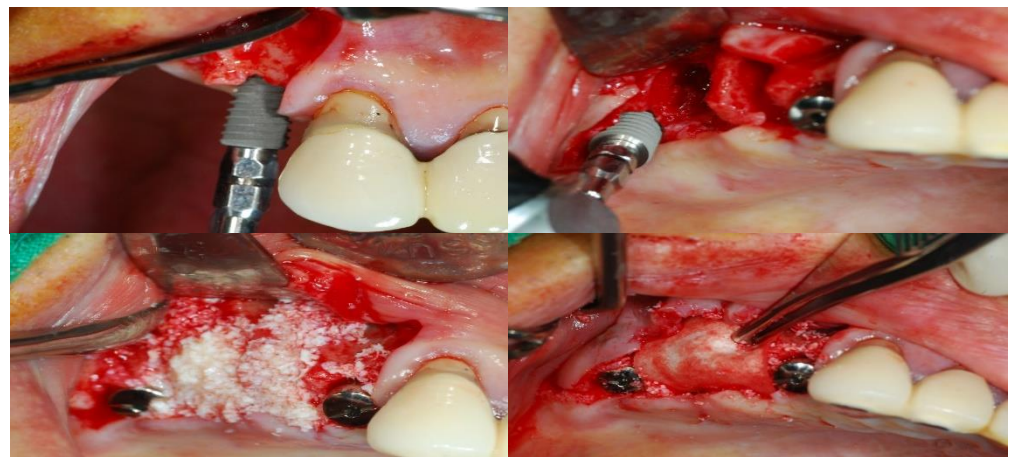
▫ **Recall Check:** April 2021

▫ **Type of Implant Used:** STERI-OSS Bone Level SD4508, SD5007



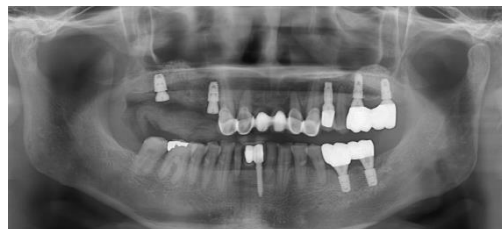Panoramic radiograph: Tooth #15 - vertical mobility, Tooth #16 - screw loosening of pre-placed implant.

Extraction and the implant removal were performed.

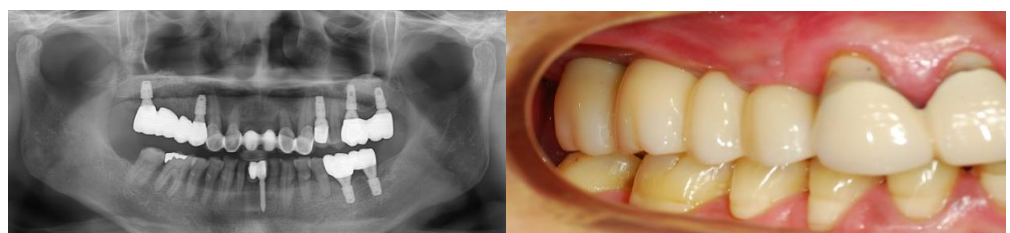


STERI-OSS Implants (SD4508 and SD5007) were placed.

The site was grafted with Xenograft material and collagen membrane was engaged between the grafting material and soft tissue.



Panoramic radiograph: Initial Implantation at #14(SD4508), #16(SD5007) in March 2019



Panoramic radiograph: Recall check in April 2021

[Case 2]

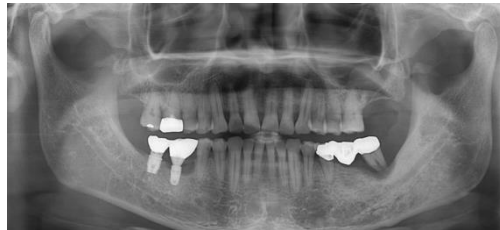Bone regeneration surgery for peri-implantitis, prosthesis preservation, and implant placement

▫ **Treatment Plan:** Due to the failure of the bridge in the left mandibular posterior region, the prosthesis was cut posterior to tooth #35 to preserve and utilize the prosthesis on #35, and an implant was planned for placement at the #36 site. Additionally, peri-implantitis was observed at the #46 site, so the prosthesis was removed, followed by treatment and bone regeneration surgery before proceeding with re-prosthetic treatment.

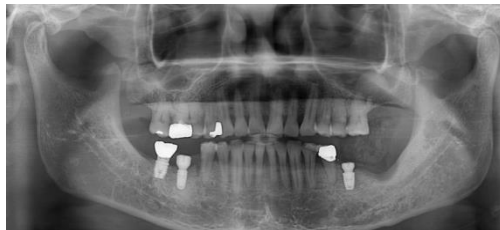▫ **Implant Placement:** April 2019

▫ **Recall Check:** March 2021

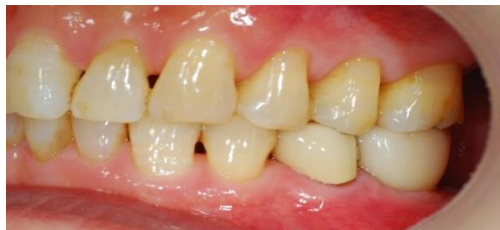▫ **Type of Implant Used:** STERI-OSS Bone Level SD5007



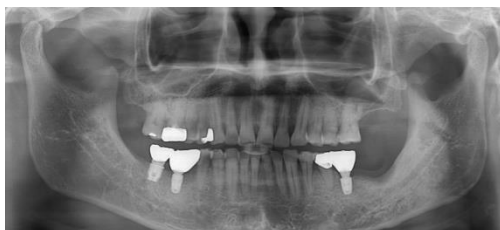Panoramic radiograph: Peri-implantitis occurred at site #46, and periodontitis developed at site #37



Panoramic radiograph: Initial Implantation at #36(SD5007) in April 2019



Final prosthesis



Panoramic radiograph: Recall check in March 2021

[Case 3]

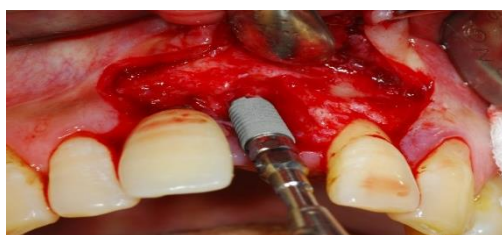Temporary prosthesis at 2 months following immediate implant placement after extraction

▫ **Treatment Plan:** Due to adult periodontitis, tooth #21 was extracted and immediately replaced with an implant. A temporary prosthesis was placed two months later, and the final prosthesis was completed after four months.

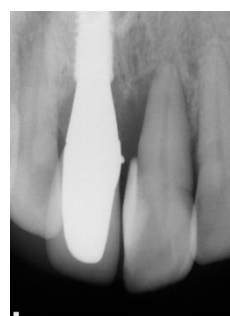
▫ **Implant Placement:** September 2019

▫ **Recall Check:** May 2021

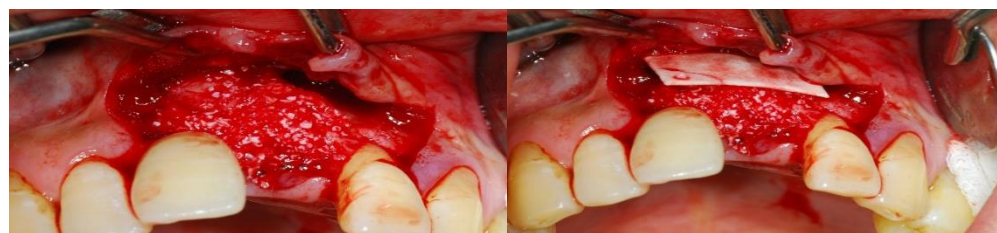▫ **Type of Implant Used:** STERI-OSS Bone Level SD4010



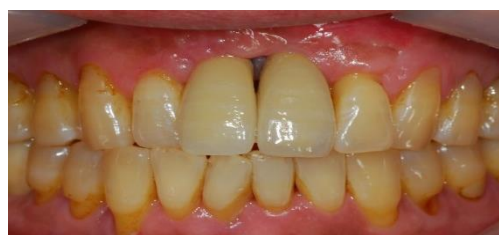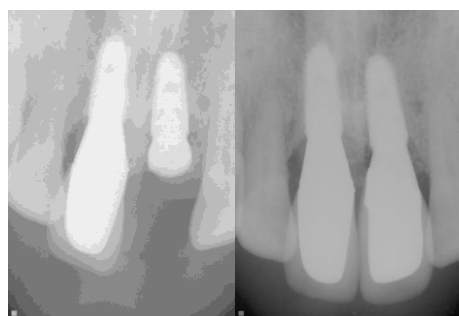
STERI-OSS Implant (SD4010) was placed.



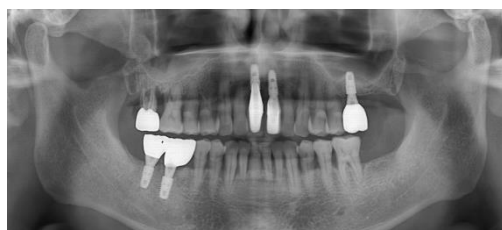Panoramic radiograph: Initial Implantation at #21(SD4010) in September 2019



The site was grafted with Xenograft material and collagen membrane was engaged between the grafting material and soft tissue.



Final prosthesis photo four months after implant placement.



Panoramic radiograph: Recall check in May 2021

[Case 4]

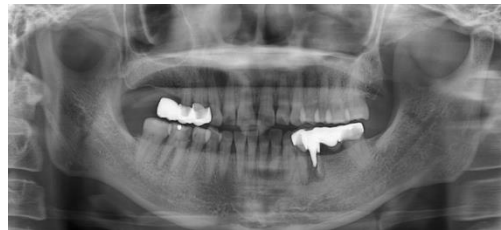Immediate and delayed implant placement after extraction of fractured and carious teeth

▫ **Treatment Plan:** In the left mandibular bridge, tooth #35 had a root fracture, and tooth #46 had severe dental caries along with a crack in the distal root. After extraction, an immediate implant was placed at the #46 site, while a delayed implant placement was planned for the left side, followed by prosthetic restoration.

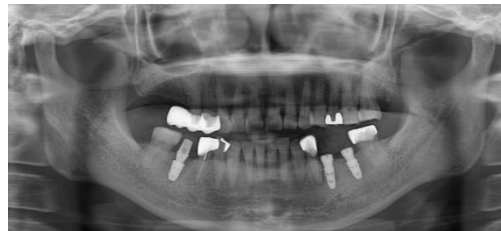▫ **Implant Placement:** June 2019

▫ **Recall Check:** April 2021

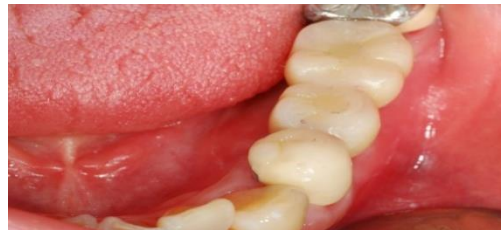▫ **Type of Implant Used:** STERI-OSS Bone Level SD5008, SD4010, SD4508



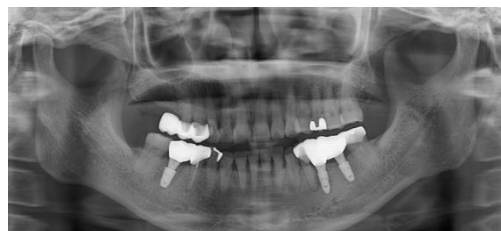Panoramic radiograph: tooth #35 had a root fracture, and tooth #46 had severe dental caries along with a crack in the distal root.



Panoramic radiograph: Initial Implantation at #35(SD4010), #37(SD4508), #46(SD5008) in June 2019



Final prosthesis



Panoramic radiograph: Recall check in April 2021

[Case 5]

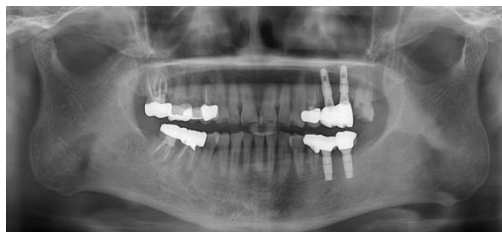Immediate implant placement after tooth extraction due to endodontic failure

▫ **Treatment Plan:** Due to endodontic failure, tooth #46 was extracted and immediately replaced with an implant, followed by prosthetic restoration.

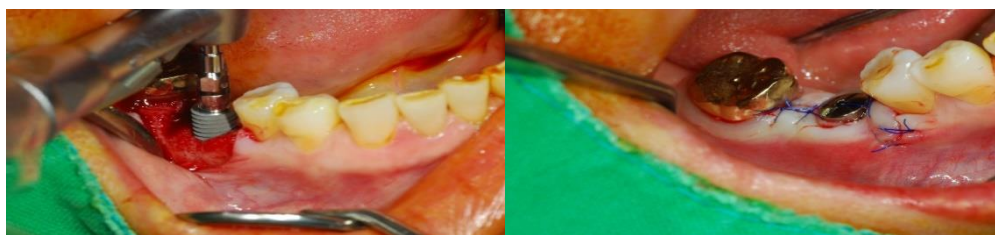
▫ **Implant Placement:** May 2019

▫ **Recall Check:** March 2021

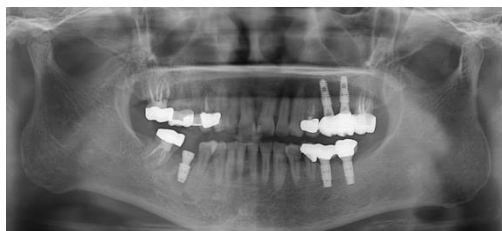▫ **Type of Implant Used:** STERI-OSS Bone Level SD5007



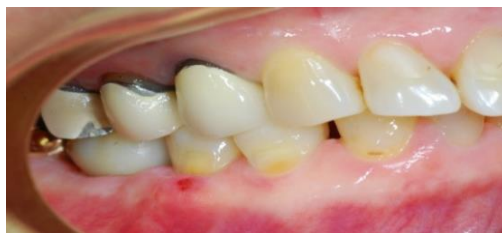Panoramic radiograph: #46 tooth is in a severe state of apical inflammation.



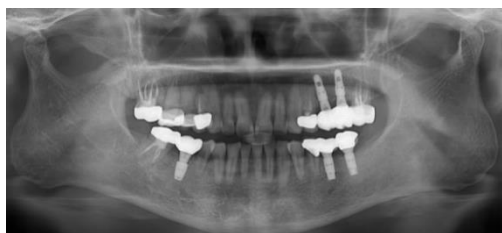STERI-OSS Implant (SD5007) was placed.



Panoramic radiograph: Initial Implantation at #46(SD5007) in May 2019



Final prosthesis



Panoramic radiograph: Recall check in March 2021

[Case 6]

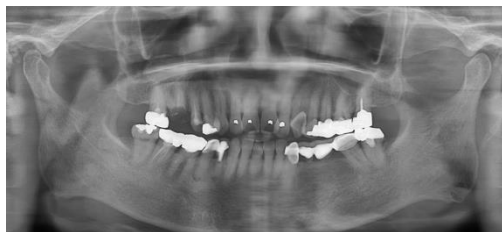Immediate implant placement after extraction of a fractured tooth

▫ **Treatment Plan:** Due to a fracture, tooth #16 was extracted and immediately replaced with an implant, followed by prosthetic restoration.

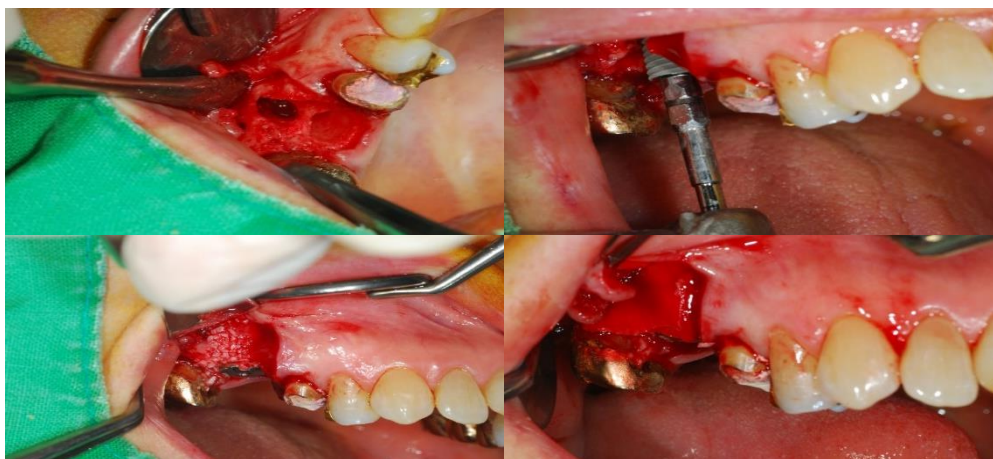
▫ **Implant Placement:** March 2019

▫ **Recall Check:** February 2021

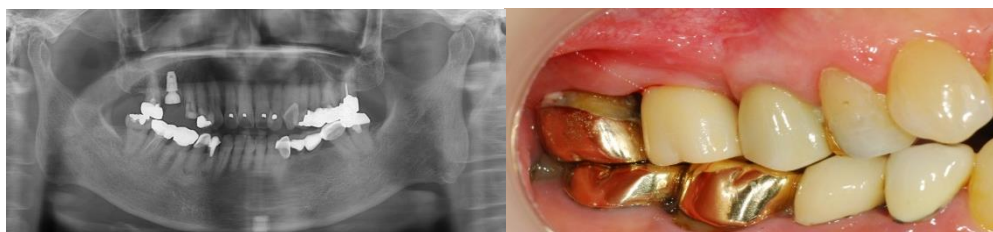▫ **Type of Implant Used:** STERI-OSS Bone Level SD5008



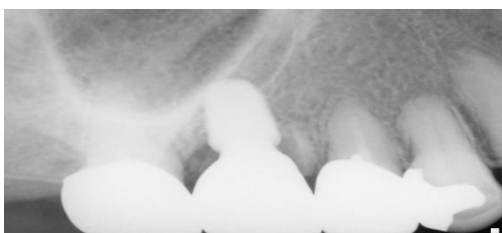Panoramic radiograph: A patient with a fractured tooth #16



#16 extracted and STERI-OSS Implant (SD5008) was placed. Bone grafting and collagen membrane were engaged.



Panoramic radiograph: Initial Implantation at #16(SD5008) in March 2019



Panoramic radiograph: Recall check in February 2021

[Case 7]

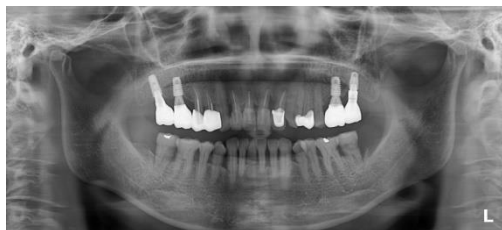Immediate implant placement following extraction of a tooth with severe cervical decay

▫ **Treatment Plan:** Due to severe cervical caries, tooth #37 was extracted and immediately replaced with an implant, followed by prosthetic restoration after two months.

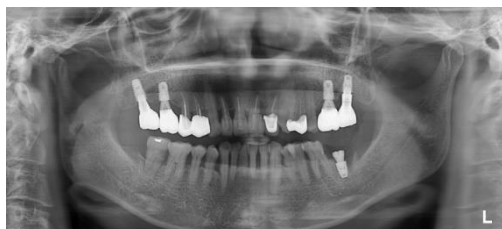▫ **Implant Placement:** September 2019

▫ **Recall Check:** October 2020

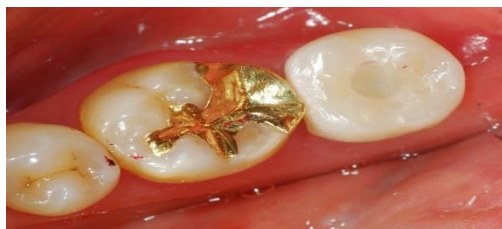▫ **Type of Implant Used:** STERI-OSS Bone Level SD5007



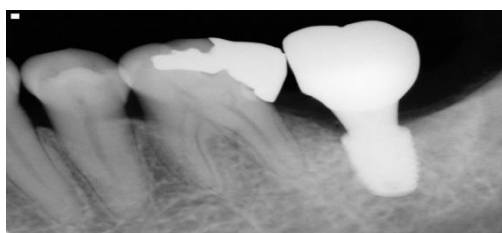
Panoramic radiograph: #37 has severe cervical caries.



Panoramic radiograph: Initial Implantation at #37(SD5007) in September 2019



Prosthetic restoration after two months



Panoramic radiograph: Recall check in October 2020

[Case 8]

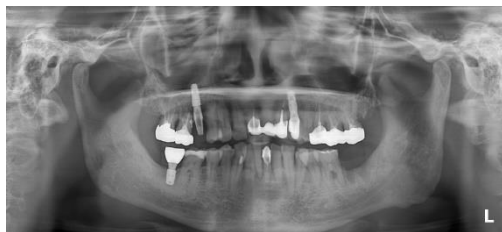Prosthetic restoration two months after implant placement

▫ **Treatment Plan:** An implant was placed at the site of the missing tooth #37, and conventional prosthetic treatment was performed two months later.

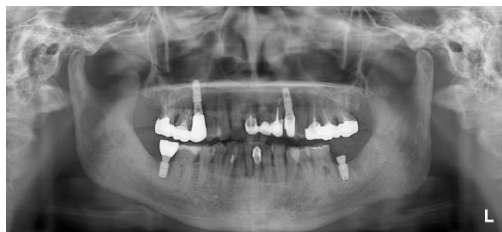▫ **Implant Placement:** April 2019

▫ **Recall Check:** April 2021

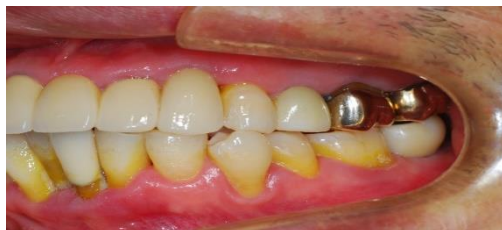▫ **Type of Implant Used:** STERI-OSS Bone Level SD5007



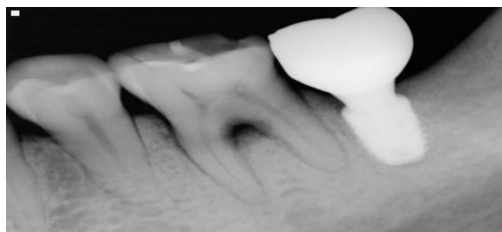
Panoramic radiograph: A patient presenting with a missing #37 tooth.



Panoramic radiograph: Initial Implantation at #37(SD5007) in April 2019



Prosthetic treatment performed two months later



Panoramic radiograph: Recall check in April 2021

[Case 9]

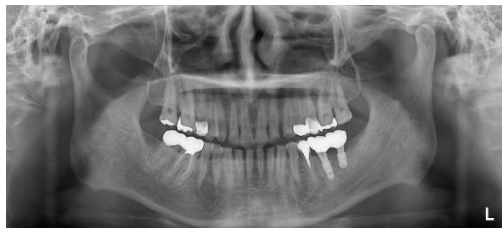*Immediate implant placement
after extraction of a failed
post crown*

▫ **Treatment Plan:** Due to the failure of the casting post in tooth #35, the tooth was extracted and immediately replaced with an implant, followed by conventional prosthetic treatment after two months.

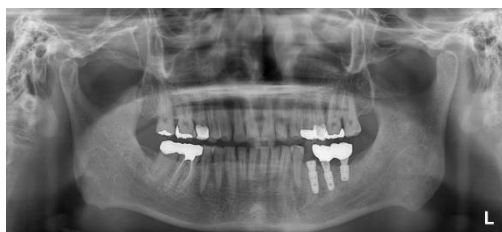▫ **Implant Placement:** May 2019

▫ **Recall Check:** February 2021

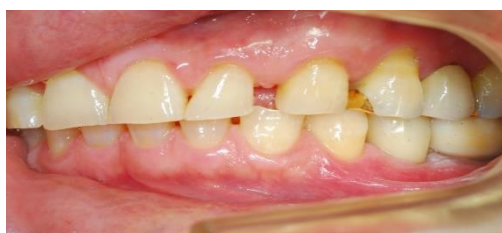▫ **Type of Implant Used:** STERI-OSS Bone Level SD4510



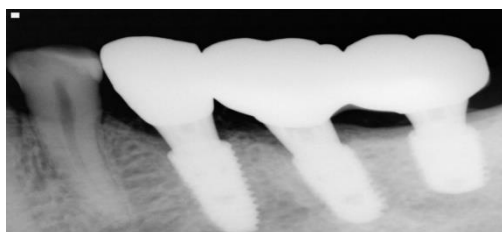
Panoramic radiograph: A fractured post crown at #35



Panoramic radiograph: Initial Implantation at #35(SD4510) in May 2019



Prosthetic treatment after two months



Panoramic radiograph: Recall check in February 2021

[Case 10]

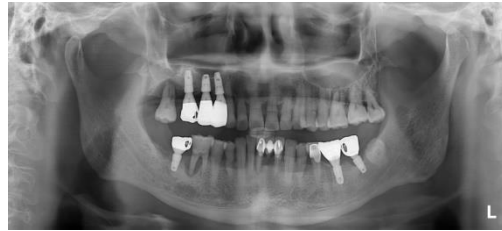Immediate implant placement after extraction of a tooth with severe periodontitis due to root crack

▫ **Treatment Plan:** Due to a root crack in tooth #46, severe periodontitis developed, leading to extraction and immediate replacement with an implant, followed by prosthetic treatment.

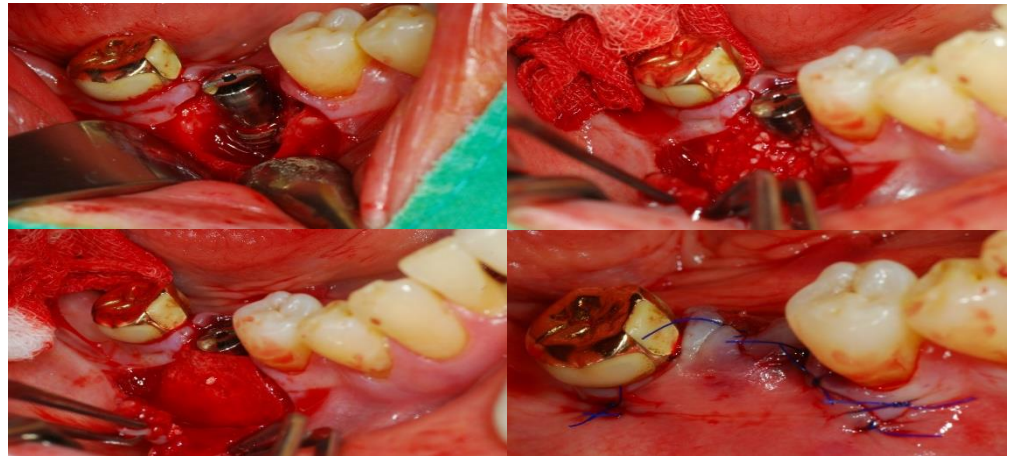
▫ **Implant Placement:** February 2019

▫ **Recall Check:** April 2021

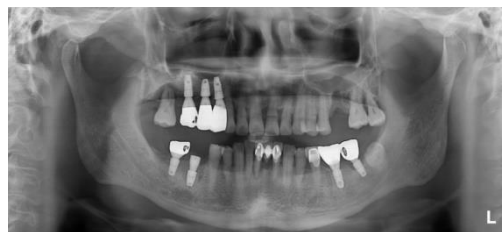▫ **Type of Implant Used:** STERI-OSS Bone Level SD5007



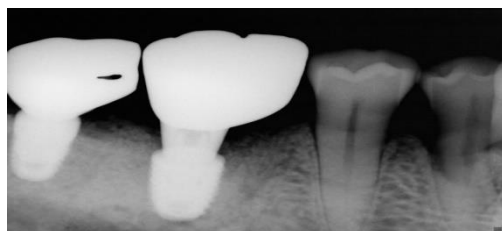
Panoramic radiograph: Tooth #46 is in a severe periodontitis condition.



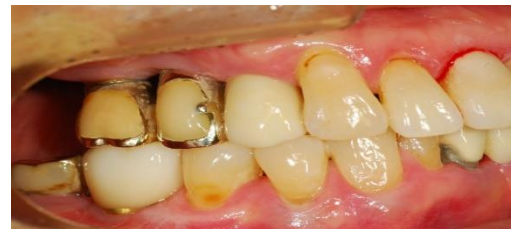STERI-OSS Implant (SD5007) was placed, followed by bone grafting and membrane engaged.



Panoramic radiograph: Initial Implantation at #46(SD5007) in February 2019



Panoramic radiograph: Recall check in April 2021



Prosthetic treatment

[Case 11]

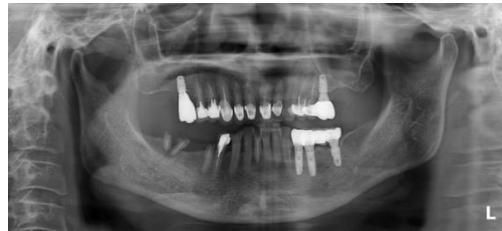Immediate implant placement following extraction of a failed bridge, with prosthetic restoration at two month

▫ **Treatment Plan:** Two implants were placed at the site of the failed right mandibular bridge, followed by conventional prosthetic treatment after approximately two months.

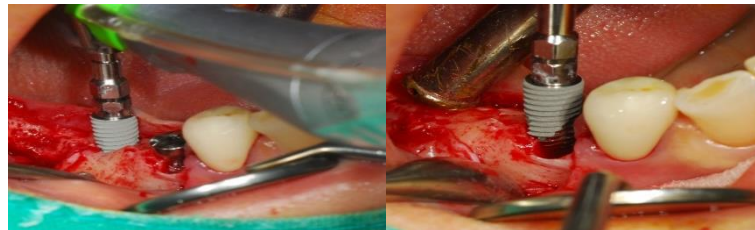▫ **Implant Placement:** July 2019

▫ **Recall Check:** March 2021

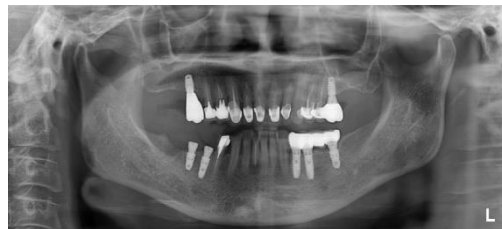▫ **Type of Implant Used:** STERI-OSS Bone Level SD4510 and SD4508



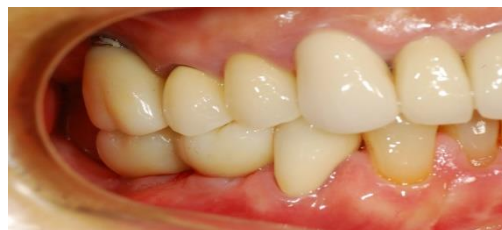Panoramic radiograph: A patient presenting with only the roots of the tooth remaining.



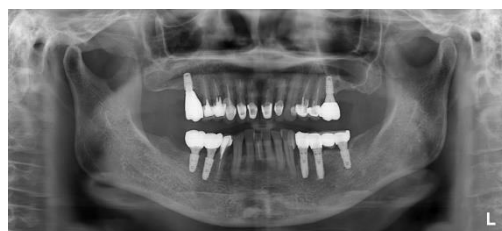STERI-OSS Implants (SD4510 and 4508) were placed.



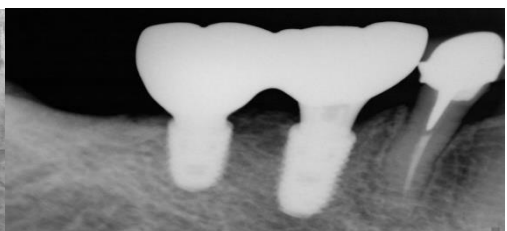
Panoramic radiograph: Initial Implantation at #46(SD4510) and #47(SD4508) in July 2019



Prosthetic treatment after approximately two months



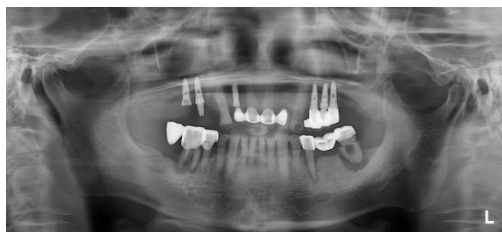Panoramic radiograph: Recall check in March 2021



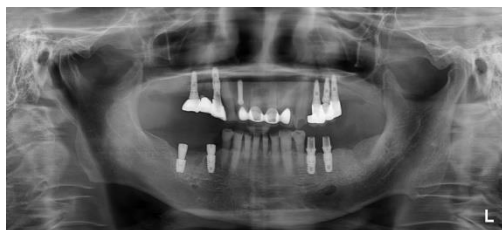[Case 12]

Immediate implant placement following extraction of a failed mandibular bridge, with final prosthetic restoration after two month

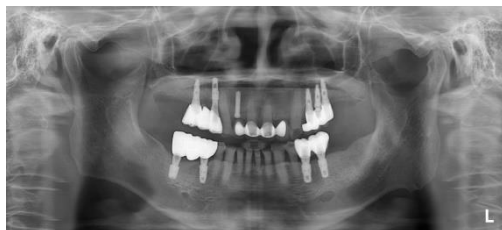- **Treatment Plan:** Two implants were placed at the site of the failed right mandibular bridge, followed by conventional prosthetic treatment after two months.
- **Implant Placement:** February 2020
- **Recall Check:** May 2021
- **Type of Implant Used:** STERI-OSS Bone Level SD4508 and SD5006



Panoramic radiograph: A patient presenting with severe periodontitis in both the left and right mandible.



Panoramic radiograph: Initial Implantation at #45(SD4508) and #47(SD5006) in February 2020



Panoramic radiograph: Recall check in May 2021

[Case 13]

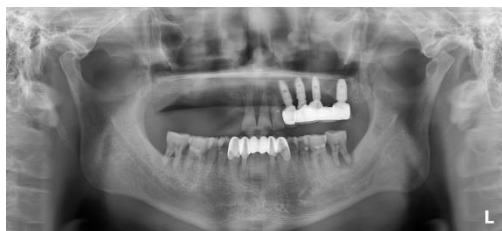Implant placement after extensive bone grafting

▫ **Treatment Plan:** Extensive bone grafting was performed at the site of the failed right maxillary bridge. After approximately four months, implants were placed, followed by conventional prosthetic treatment starting two months later.

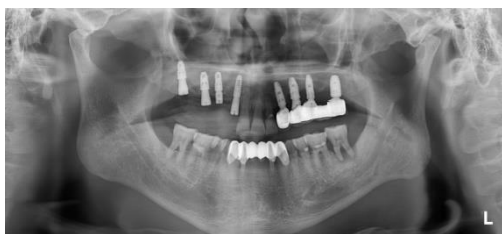▫ **Implant Placement:** March 2020

▫ **Recall Check:** May 2021

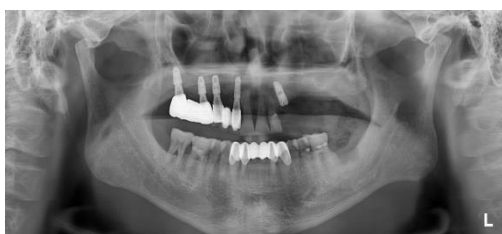▫ **Type of Implant Used:** STERI-OSS Bone Level SD4508 and SD4508



Panoramic radiograph: The right maxilla has a very low bone volume.



Panoramic radiograph: Initial Implantation at #15(SD4508), #17(SD4508) in March 2020



Panoramic radiograph: Recall check in May 2021

MEMO

Designed for Confidence. Proven Stability.

STERI-OSS IMPLANT

MEMO

Designed for Confidence. Proven Stability.

STERI-OSS IMPLANT

